

# Understanding Partial Trisomy of Chromosome 7q: Inheritance Patterns and Congenital Anomalies in a Newborn

García L.<sup>1</sup>, López M.<sup>2</sup>, Rodríguez P.<sup>3</sup>, Martínez A.<sup>4</sup>, Torres J.<sup>5</sup>

<sup>1</sup>Department of Biotechnology, University of Barcelona, Barcelona, 08028, Spain

<sup>2</sup>Department of Chemistry, University of Valencia, Valencia, 46101, Spain

<sup>3</sup>Department of Environmental Engineering, Polytechnic University of Catalonia, Barcelona, 08034, Spain

<sup>4</sup>Institute of Physics, University of Madrid, Madrid, 28040, Spain

<sup>5</sup>Department of Electrical Engineering, University of Seville, Seville, 41012, Spain

## Abstract

We report on a familial translocation  $t(3;7)(3q29::7q22)$  leading to pure trisomy  $7q22 \rightarrow 7qter$  in a 21-days-old boy:  $46,XY,der(3;7)(3pter \rightarrow 3q29::7q22 \rightarrow 7pter)$ . By conventional cytogenetic techniques including fluorescence in situ hybridization (FISH) analysis, the patient was found to have inherited a derivative chromosome 3 from his father:  $46,XY,t(3;7)(3pter \rightarrow 3q29::7q22 \rightarrow 7qter;7pter \rightarrow 7q22)$ . As a consequence, pure duplications of chromosome 7q have been classified in 4 groups on the basis of the involved region. The present case is included in group 2 which involves large duplications spanning from proximal bands to telomere duplication. In the literature, only one case with a pure duplication of the same region has been described. Despite this, the phenotype is different. Moreover, our patient shares some phenotypic features, such as wide fontanelle, retrognathia, epicathal fold, hypertelorism, pulmonary hypoventilation and early postnatal death. However, the absence of physical characterization in most of the reported cases could justify the lacking phenotype-genotype correlation in patients with partial 7q duplication. Further studies using recent molecular approaches such as array-CGH might permit a more clinically useful grouping of 7q duplications.

## Keywords:

*Translocation;*  
*chromosome 7;*  
*pure trisomy;*  
*FISH*

## Introduction

The prevalence of balanced chromosome aberrations (including translocations, paracentric and pericentric inversions, and other rearrangements) in normal populations is approximately 1 in 500 (Gardner RM 2004). Translocation and inversion carriers are usually phenotypically normal, but meiotic segregation errors may lead to fertility problems and an increased risk (5-30%) for spontaneous abortions and/or chromosomally unbalanced offspring. Duplications of the long arm of chromosome 7 are very rare (Back E. 2001). To date, more than 55 cases of duplication 7q have been reported most as an unbalanced aberration from a consequence of an inheritance of a parental balanced chromosomal rearrangement (Verma, Conte et al. 1992; Megarbane, Gosset et al. 2000; Ndah, Stead et al. 2000; Robinet, Douvier et al. 2000; Zelante, Croce et al. 2003). As a consequence, 7q duplication results in variable clinical manifestations due to different content of the unbalanced rearrangement and also to the involvement of extra chromosomal material from other chromosomes (Forabosco, Baroncini et al. 1988; Goodman, Stone et al. 1999; Back E. 2001; Scelsa, Bedeschi et al. 2008; Chen, Su et al. 2012; Shojaei, Behjati et al. 2013). Twenty three cases of isolated 7q duplication with no additional deletion of other chromosomes have been reported (Scelsa, Bedeschi et al. 2008; Alfonsi, Palka et al. 2012).

In an attempt to correlate phenotype with karyotype, in patients with pure  $dup(7q)$  syndrome, Scelsa et al. (2008) (Scelsa, Bedeschi et al. 2008) have suggested grouping the reported cases into 4 classes: group 1 includes patients with entire arm duplication (Wahrman, Cohen et al. 1978; Ndah, Stead et al. 2000); group 2 is a heterogeneous group with large duplications spanning from proximal bands to telomere (Courtens, Vroman et al. 2001; Rodriguez, Lopez et al. 2002); group 3 includes interstitial duplications of different sizes, having, in most of the reported cases, the proximal breakpoint located between 7q21 and 7q22 (Grace, Sutherland et al. 1973; Hoo,

Lorenz et al. 1982; Kardon, Pollack et al. 1983; Romain, Cairney et al. 1990; Stratton, DuPont et al. 1993; Lukusa and Fryns 1998; Megarbane, Gosset et al. 2000; Gardner RM 2004). Group 4 includes distal duplications(Grace, Sutherland et al. 1973; Bartsch, Kalbe et al. 1990; Romain, Cairney et al. 1990; Haslam and Norman 1992; Verma, Conte et al. 1992; Rodriguez L. 2005; Scelsa, Bedeschi et al. 2008; Xiao, Ji et al. 2011). Nevertheless, genotype-phenotype correlation is still ill defined or poorly delineated(Novales, Fernandez-Novoa et al. 1982; Forabosco, Baroncini et al. 1988; Stratton, DuPont et al. 1993; Rodriguez L. 2005).

Here we report on a 21-days-old boy with partial pure trisomy of the long arm of chromosome 7. The propositus karyotype was 46,XY,der(3;7)(3pter→3q29::7q22→7pter). The patient was found to have inherited a derivative chromosome 3 from his father. To our knowledge there have not previous report with the same translocation: t(3;7)(3q29::7q22).

## Materials and methods

### *Chromosome preparation and conventional karyotyping*

Cytogenetic investigation using GTG banding technique was performed on metaphase spreads of peripheral blood lymphocytes via standard procedures. Cytogenetic analysis was performed on GTG-banded metaphases from the patient and subsequently of the parents at a resolution of 450 bands according to standard lab protocol. Chromosome analyses were also performed on cultured blood lymphocytes from unaffected pedigree members (III-8 and III-9, **Figure 1**). Twenty metaphases were analyzed for each individual sample. Karyotype was described according to ISCN 2009. All samples used in this study were collected with appropriate informed consent.

### *Fluorescence in situ hybridization (FISH)*

FISH analysis with whole chromosome paint (WCP 3) for chromosome 3, (WCP 7) for chromosome 7, qter for chromosome 7 (qter7) and centromeric region of chromosome 3 (cen3) (Cytocell Ltd, Cambridge, UK.) was performed according to manufacturer's instructions on proband and father's metaphase preparations.

## Results

### *Clinical report*

The male propositus is the third child of healthy non-consanguineous parents, a 38-year old mother and a 46-year-old father, the first and second child show a normal development according to age.

Mother present negative serology, with hypertension induced by pregnancy and preterm labor. There was maternal and paternal family history of deceased children and maturational delay, without consanguinity. Two half brothers, by the father, with multiple malformations died in perinatal period. (**Figure 1**).

The pregnancy was complicated by hypertension and childbirth threat. The boy was delivered by cesarean section. He was born at 34 weeks of gestation. APGAR score was 5/8. Birth weight was 2.200 g, length was 43 cm, and the occipitofrontal circumference (OFC) was 42.5 cm (50<sup>th</sup>-75<sup>th</sup> percentile). The newborn showed severe respiratory distress, bilateral pulmonary hypoventilation and intermittent tachypnea. No cardiac malformations were diagnosed by Colour Doppler Echocardiography. Ultrasound of the brain demonstrated agenesis of corpus callosum. Severe retardation of maturational patterns. Hypotonia.

Dysmorphic features include: Relative macrocephaly, unusual facies, high forehead, high and bossing fontanelle, retrognathia, epicanthic fold, mammary hypertelorism, hyperchromic spot on thorax, dysplastic ears, a broad nasal bridge, short and wide neck, downslanting palpebral fissure, hands with tapered fingers and mobility restriction. Umbilical granuloma. Angioma. The genitalia were male phenotype with increased scrotum volume and micropenis. Because of further clinical findings a karyotype analysis was performed (see below).

During the seven months of the boy's life showed severe asphyxia with oxygen requirement. Postnatal growth retardation and developmental delay became evident. Recurrent omphalitis. The boy showed hyperglycemia and feeding difficulties: absence of suction-deglutition reflex. Exclusive enteral feeding.

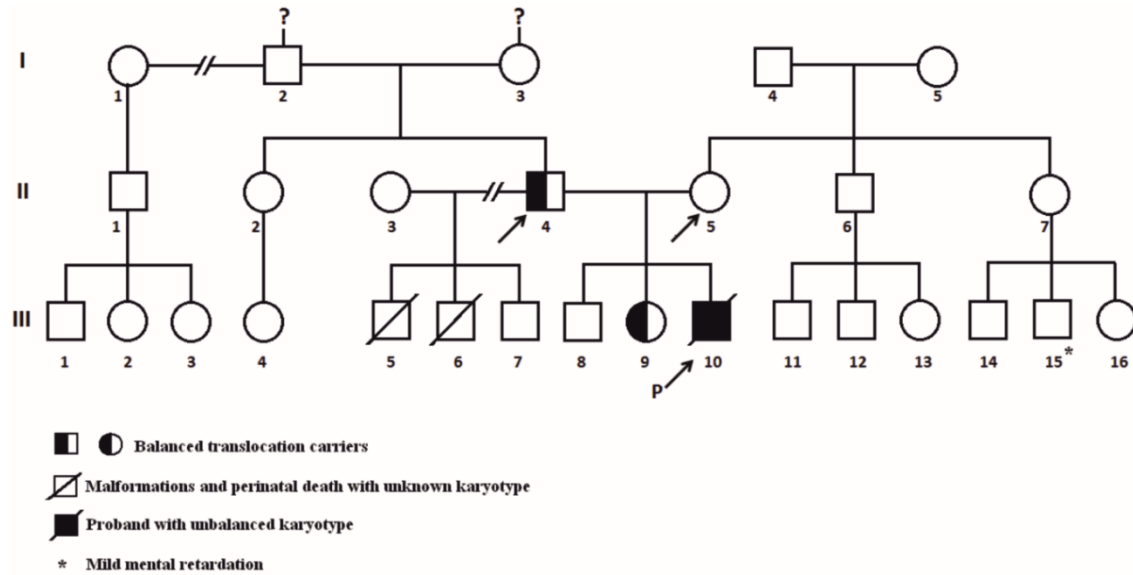


Figure 1. Pedigree of the family. Proband's mother has a normal karyotype and the father is carrier of a balanced translocation. Only these family members were tested. Only in the proband and in the father, both cytogenetic and FISH testing were performed.

**Cytogenetic characterization and FISH**

Chromosome analysis in the proband was performed on peripheral blood lymphocytes according to standard techniques and revealed a derivative chromosome 3. Chromosome analysis of the parents revealed a normal female karyotype in the mother and a balanced translocation between long arms of chromosomes 3 and 7: 46,XY,t(3;7)(3pter→3q29::7q22→7qter;7pter→7q22) in 20 metaphases analyzed (karyotype described according to ISCN 2009) in the father. This unmasked the derivative chromosome 3 of the proband as the result of a malsegregation of the complex paternal translocation. The boy inherited the derivative chromosome 3 but a normal chromosome 7 from the father resulting in isolated partial trisomy 7q22 to 7qter (**Figure 2**).

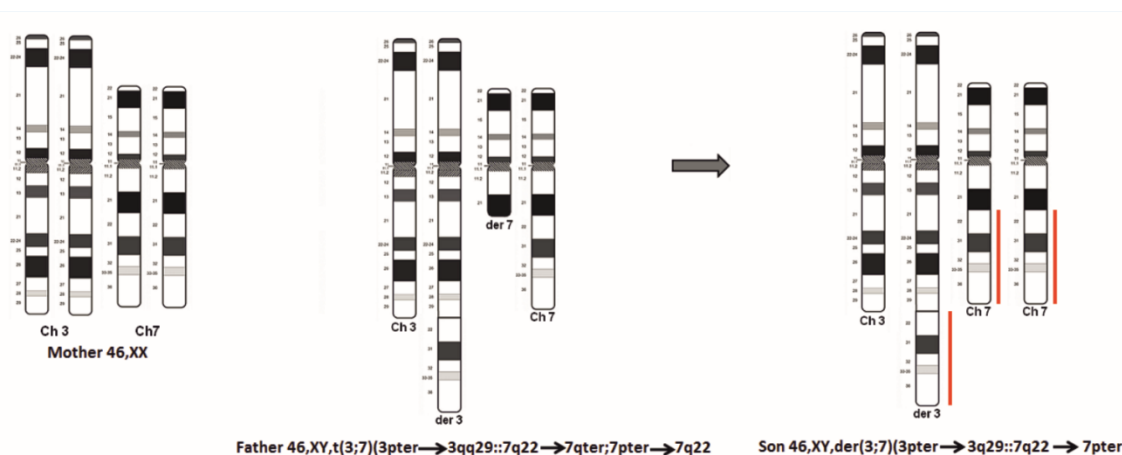


Figure 2. Partial ideogram showing the inherited derivative chromosome 3 but a normal chromosome 7 from the father resulting in isolated partial trisomy 7q22 to 7qter.

Because of the paternal rearrangement karyotype was performed in the proband's brothers revealing a balanced translocation in his sister with normal phenotype (**Figure 1**).

Conventional chromosomal analysis from the proband showed an unbalanced karyotype with additional material on the terminal end of the long arm of chromosome 3. Partial trisomy 7q was detected that includes the segment

between q22 band to q terminal. Proband karyotype was 46,XY,der(3;7)(3pter→3q29::7q22→7pter). (**Figure 3**). The banding patterns indicated that no chromosome 3 material was lost during the translocation.

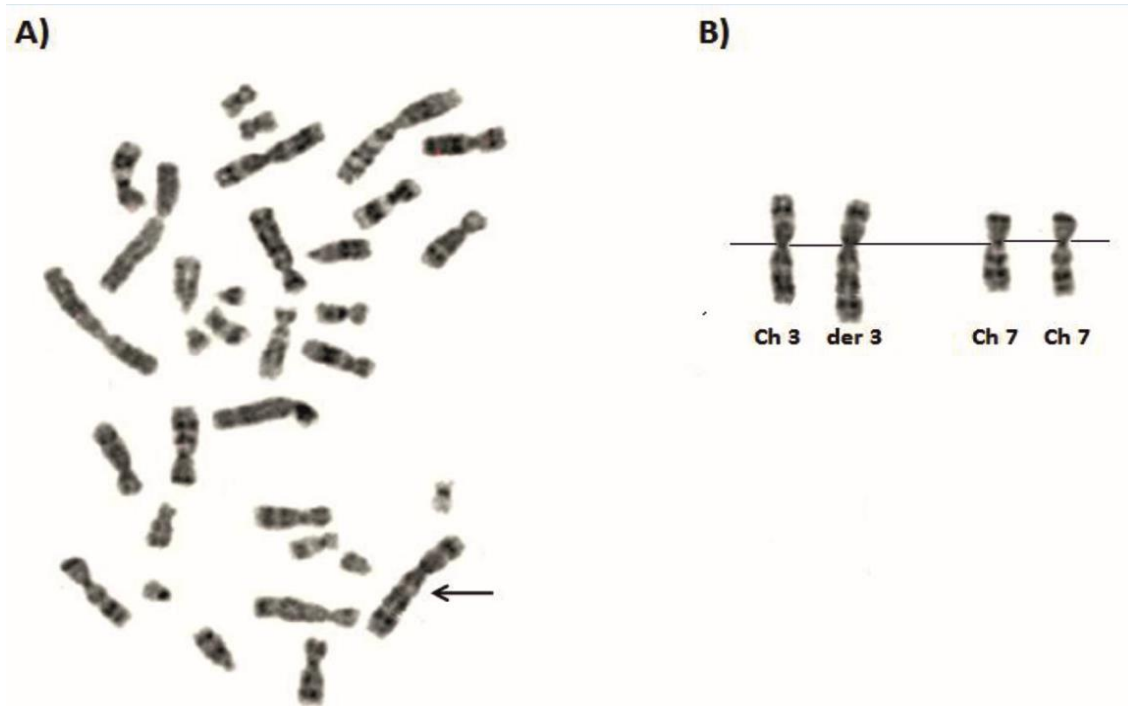


Figure 3. A) Partial routine G banded karyotype of the proband. The arrow indicates the der 3 chromosome. B) Partial trisomy 7q karyotype.

His mother's karyotype was normal 46,XX but his father showed a balanced translocation between long arms of chromosomes 3 and 7: 46,XY,t(3;7)(3pter→3q29::7q22→7qter;7pter→7q22). (**Figure 4**).

Translocation of chromosome 3 and 7 was confirmed in the father's proband by FISH studies using whole-chromosome painting (WCP) probes for chromosomes 3 and 7, centromeric region of chromosome 3 (cen3) and 7qter region. WCP FISH results showed that the region 7q22-qter was present on the derivative chromosome 3. There was neither a gap in the WCP 3 signals along the derivative chromosome 3 nor were there signals on a heterologous chromosome as expected in the case of a complex translocation. The cen3 and 7qter probes present on derivative chromosome 3 further characterized the translocation between chromosome 3 and chromosome 7 (**Figure 5**). Derivative chromosome 3 was confirmed in the proband by WCP 3, the FISH results showed that there was neither a gap in the WCP 3 signals along the derivative chromosome 3 nor were there signals on a heterologous chromosome (**Figure 5**)

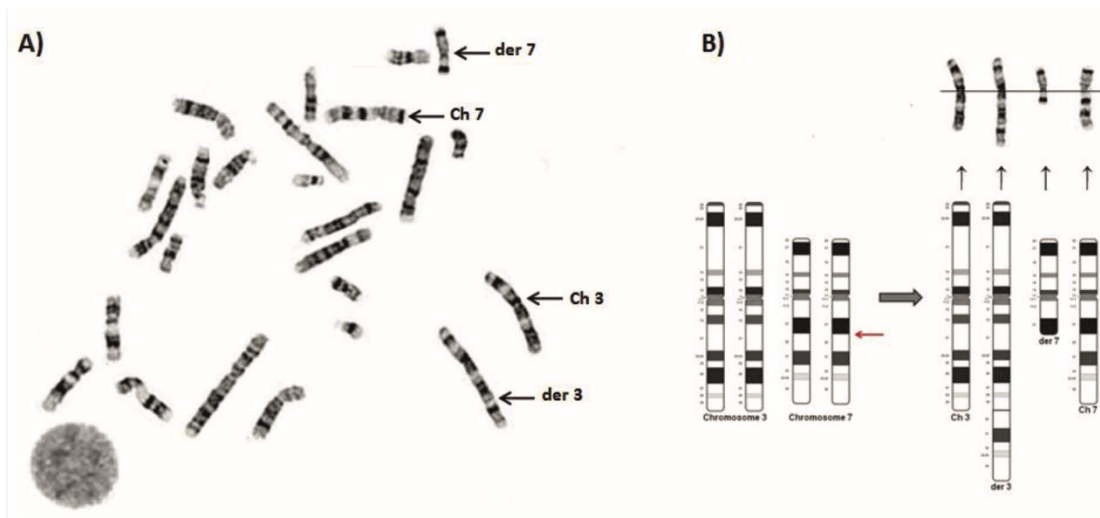


Figure 4. A) Partial routine G banded karyotype of the father, 46,XY,t(3;7)(3pter→3q29::7q22→7qter;7pter→7q22). B) Partial chromosome 7 karyotype is shown with the arrows indicating where the breakpoint in chromosome 7 occurred.

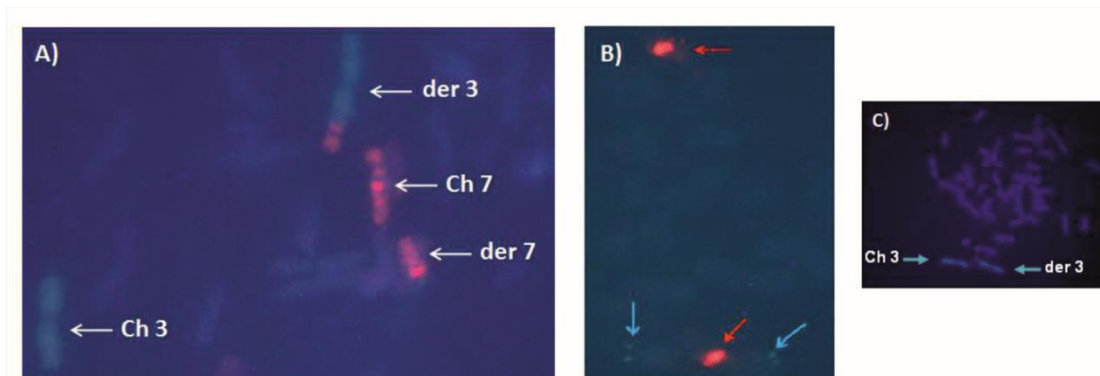


Figure 5. FISH results of the father's proband and of the proband. A) WCP3 (green) paints the normal chromosome 3 and part of the derivative chromosome 3; WCP7 (red) paints the normal chromosome 7 and derivative chromosome 7. The derivative chromosome 3 shows an extra red band. B) Centromeric region of chromosome 3 (turquoise arrows) are shown in the normal chromosome 3 and in the derivative chromosome 3. The 7qter (red arrows) probe are shown in the normal chromosome 7 and in the derivative chromosome 3. C) FISH with WCP probe for chromosome 3 of the proband.

## Discussion

A series of reports describing different segments in relation to partial trisomy 7q have been published since 1972, and the discussions in these studies have dealt with the correlations of these trisomies to one or more syndromes. In 1974 Berger et al (Berger, Derre et al. 1974). defined two different partial trisomy 7q syndromes: The first involved bands 7q→7qter and was characterized by low birth weight, growth and mental retardation, cranial abnormalities, absence of microcephaly, cleft palate, low-set ears, anomalies of muscular tone, and psychomotor retardation; the second syndrome was associated with trisomy of bands 7q21 or 22→q31 and was characterized by narrow palpebral fissures, epicanthus, flattened nasal bridge, absence of microretrognathia and cleft palate, hypotonicity, and growth retardation. Turleau et al. (1976) (Turleau, Rossier et al. 1976) when describing a new case questioned this definition of the two syndromes as different entities. Later, Vogel et al. (1977) (Vogel W. 1977) reviewed the published cases and identified trisomy 7q31→7qter as a clearly differentiated syndrome within the group of partial trisomies 7q, the features being low birth weight, retardation of development, cleft palate, microretrognathia, small nose, hypertelorism, small palpebral fissures, and occasional skeletal anomalies. Schmid et al. (1979) (Schmid M. 1979) found the common features of trisomies 7q32→7qter to be low birth weight, developmental retardation, high forehead with broadly protruding ossa parietalis, wide and flattened nasal bridge, short neck, deep-scated ears, and tendency to hypertelorism and epicanthus. They also pointed out the absence of micrognathia and cleft palate as a

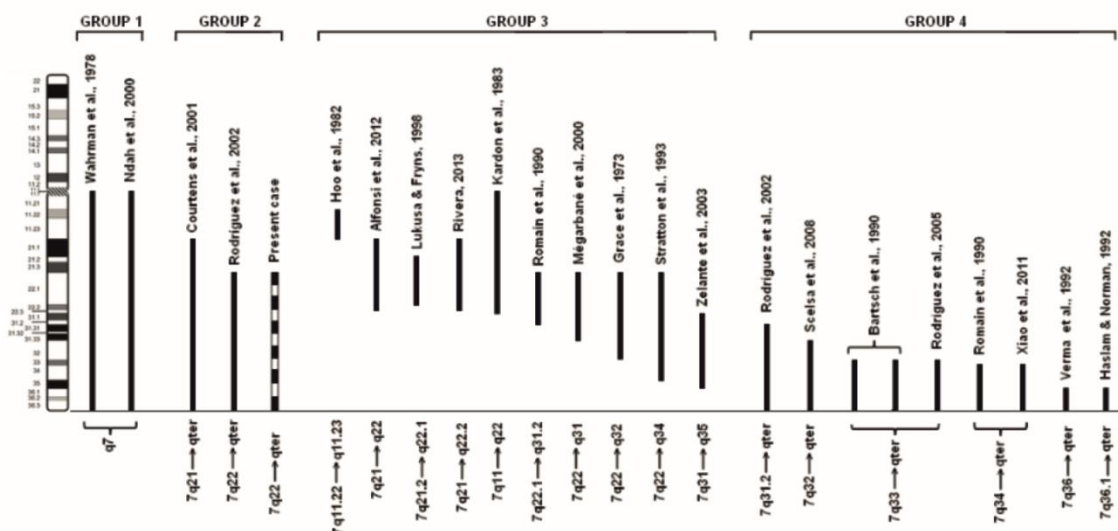
characteristic which distinguishes it from other trisomies 7q and therefore makes it possible to define the clinical syndrome for the trisomy of the segment 7(q32→qter).

Novales and co-workers suggested three groups (Novales, Fernandez-Novoa et al. 1982). Patients with a duplication 7q21 or q22 → 7q31 belong to group 1. The phenotype includes facial dysmorphism (frontal bossing, narrow palpebral fissures, epicanthus, and hypertelorism), strabism, hypotonia, and developmental delay. Group 2 includes patients with duplication 7q31 → 7qter. The phenotype is characterized by low birth weight, large fontanel, facial dysmorphism (narrow palpebral fissures, hypertelorism, small nose, low-set and malformed ears, microretrognathia), cleft palate, developmental delay, skeletal anomalies, and a reduced life expectancy. Group 3 is defined by a duplication of 7q32 → 7qter. These patients show low birth weight, facial dysmorphism (low-set ears, small nose, and hypotonia), kyphoscoliosis, skeletal anomalies, hypotonia and developmental delay. Courtens et al. (2001) (Ndah, Stead et al. 2000) described group 4 with a duplication involving 7q21 or q22 → 7qter.

There are many publications on partial trisomies in 7q. Most cases described with a partial trisomy 7q arm resulted from a balanced familial translocation involving the long arm of chromosome 7 and another chromosome leading to partial trisomy/monosomy 7 and partial trisomy/monosomy of the translocation partner, respectively (Bass, Sparkes et al. 1985; Couzin, Haites et al. 1986; Tsui 1988; Slavotinek, Maher et al. 1997; Stetten, Charity et al. 1997; Goodman, Stone et al. 1999; Speleman, Callens et al. 2000; Rodriguez, Lopez et al. 2002; Scelsa, Bedeschi et al. 2008; Tchirikov, Merinsky et al. 2010). The rest of the cases are of terminal trisomies produced by a) complex parental translocations (Felding and Mitelman 1979); b) parental inversion (Winsor, Palmer et al. 1978); c) terminal parental translocation (Novales, Fernandez-Novoa et al. 1982).

Trisomy 7q produces abnormalities affecting virtually every system in the body including the central nervous system, the face, the musculoskeletal system, the heart, and the genitourinary system, but the combination of specific malformations may vary among patients.

Cases with a 7q pure duplication are uncommon, although there are about 23 reported cases of different 7q segments with a pure duplication with no additional deletion of other chromosomes. As a consequence, duplications of chromosome 7q have been classified in 4 groups on the basis of the involved region (Scelsa, Bedeschi et al. 2008). The present case is included in group 2 which involves a heterogeneous large duplications spanning from proximal bands to telomere (**Figure 6**).



**Figure 6.** Chromosome 7 ideogram with the 23 cases of pure trisomies in 7q, ordered by groups according to the classification revised by Scelsa et al. (2008).

Of all previously reported cases of pure trisomy 7q, there has been only one reported case involving partial pure trisomy 7q22 → 7qter (Rodriguez, Lopez et al. 2002); we report the second case. On the basis of 7q duplicated

region, we compared our patient's clinical and cytogenetic findings with those of the other patient with similar 7q duplication previously reported. The patient described herein and the reported case have partial pure trisomy 7q22 → 7qter, they therefore fit best into group 4 proposed by Courtens et al. (2001)(Courtens, Vroman et al. 2001) and group 2 proposed by Scelsa et al. (2008)(Scelsa, Bedeschi et al. 2008). Despite this, the phenotype is different. Our case showed a number of features similar to the previously reported case(Rodríguez, Lopez et al. 2002) including low birth weight, wide open fontanelle, hypotonia, respiratory insufficiency and early postnatal death. In contrast to other descriptions our patient does not share some phenotypic features, such as cleft palate, skeletal anomalies, kyphoscoliosis and cardiac defects. The features in our case not reported by Rodríguez et al. (2002)(Rodríguez, Lopez et al. 2002) include relative macrocephaly, downslanting palpebral fissure, epicanthal fold, broad nasal bridge, ear abnormalities, short and wide neck, retrognathia, frontal bossing, mammary hypertelorism, genital defects and agenesis of corpus callosum. Rodríguez et al. (2002)(Rodríguez, Lopez et al. 2002) do not have a correct description of the facial features of this child, and there were no photographs available, but the child probably had several of the facial manifestations described in our patient (**Table 1**).

However, the absence of physical characterization in most of the reported cases, herein the case reported by Rodríguez et al. (2002)(Rodríguez, Lopez et al. 2002), could justify the lacking phenotype-genotype correlation in patients with partial 7q duplication.

In the other hand, clinical findings for duplications for 7q22q31, 7q31qter, and 7q32qter have been well accepted as having characteristic abnormalities(Novales, Fernandez-Novoa et al. 1982; Johnson, Michels et al. 1986). Thus, a genotype-phenotype correlation is difficult to establish due to the high number of genes and transcripts mapping in the duplicated region, many of which are imprinted. Further studies using molecular approaches such as array-CGH might permit a more clinically useful grouping of 7q duplications.

The majority of reports of partial trisomy 7 result from a parental balanced translocation (reciprocal or insertion) or inversion 7. The most common familial rearrangements are translocations. In case of an unbalanced segregation in an offspring the resulting imbalances consist of a combination of partial trisomy and partial monosomy. In most of the cases it is impossible to exactly relate the phenotypic consequences of an unbalanced translocation to either the underlying partial trisomy or the partial monosomy.

One point of importance is the large sampling errors associated with these syndromes due to the small populations involved. It underlines the need for the publication of the major clinical features of all such patients encountered.

Another complication is the obvious variation in the stigmata present between subjects with apparently the same partial trisomy imbalance. It may be that this is mainly due to the different monosomies present in each case. It is well recognized that chromosomal deletions have a much greater clinical effect than similar sized trisomies. However, even when the partially trisomic subjects are of the same family and consequently have identical monosomies, noticeable phenotypic differences exist. Variation in the phenotype may also be due to small interfamilial variability in the size of the partial trisomy.

Another difficulty in the description of phenotypic consequences of a certain chromosomal imbalance is the breakpoint designation. The precise description of the breakpoint is important for the genotype-phenotype correlation. In solely cytogenetically investigated patients, breakpoint designation remains doubtful due to the limited resolution of chromosome banding techniques. In recent years comparative genomic hybridization (CGH) such as array-CGH has overcome many of the limitations of classical chromosomal banding analysis and can estimate the breakpoints with an accuracy of some kb.

The patient described herein has apparently isolated partial trisomy 7q22 → 7qter without additional chromosomal imbalances. The precise description of the breakpoint should be confirmed by array-CGH. In the study of this family, we identified two balanced translocation carriers and one unbalanced patient, and genetic counseling was offered to the family.

*Table 1. Clinical and cytogenetic data of the present case and the reported patient with a same 7q pure trisomy.*

	Rodriguez et al., 2002 *	Present case	Total
Chromosome 7q segment	7q22---qter	7q22---qter	
Low birth weight	+	+	2/2
Relative macrocephaly		+	1/2
Wide open fontanelle,	+	+	2/2
Hypotonia	+	+	2/2
Downslanting palpebral fissure		+	1/2
Hypertelorism		+	1/2
Broad nasal bridge		+	1/2
Short and wide neck		+	1/2
Ear abnormalities		+	1/2
Cleft palate	+		1/2
Epicathal fold		+	1/2
Microretrognathia/retrognathia		+	1/2
Frontal bossing		+	1/2
Genital defects		+	1/2
Early postnatal death	+	+	2/2
Respiratory insufficiency	+	+	2/2
Skeletal anomalies	+		1/2
Kyphoscoliosis	+		1/2
Agenesis of corpus callosum		+	1/2
Cardiac defects	+		1/2

\*They do not have a correct description of the facial features of this child, and there were no photographs available, but she probably had several of the facial manifestations described in this type of trisomy. Because the parents of this patient refused necropsy, there is no information on possible internal malformations.

## Conclusion

This case illustrates a partial trisomy 7q syndrome, 46,XY,der(3;7)(3pter→3q29::7q22→7pter), derived from a paternal balanced no reciprocal translocation, 46,XY,t(3;7)(3pter→3q29::7q22→7qter;7pter→7q22). Because the chromosomal rearrangement involves the complete long arm of chromosome 3; the phenotype corresponds to a pure trisomy 7q22→qter. The report of this family is important because this is the first report of translocation : t(3;7)(3q29::7q22).

Phenotype analysis of the present case would be helpful for further delineating the genotype-phenotype correlation of partial trisomy 7q. Moreover, high resolution array CGH is a valuable tool for precise characterization of breakpoints in chromosomal imbalances and better genotype-phenotype correlation.

## Competing interest

The authors declare no competing interests.

## Acknowledgments

The authors thank the family for their support of this study.

## References

1. Alfonsi, M., C. Palka, et al. (2012). "A new case of pure partial 7q duplication." *Cytogenet Genome Res* 136(1): 1-5.
2. Back E., T. R., Fuchshuber A. (2001). "De novo inverted duplication of chromosome 7(q21.3-q35) cytogenetics diagnosis confirmed byFISH analysis." *Clin Genet* 60: 77-82.
3. Bartsch, O., U. Kalbe, et al. (1990). "Clinical diagnosis of partial duplication 7q." *Am J Med Genet* 37(2): 254-257.

4. Bass, H. N., R. S. Sparkes, et al. (1985). "A family with three independent autosomal translocations associated with 7q32---7qter syndrome." *J Med Genet* 22(1): 59-63.
5. Berger, R., J. Derre, et al. (1974). "[Partial trisomies of the long arm of 7 chromosome]." *Nouv Presse Med* 3(29): 1801-1804.
6. Courtens, W., S. Vroman, et al. (2001). "Pre- and perinatal findings in partial trisomy 7q resulting from balanced parental translocations t(7;21) and t(4;7)." *Prenat Diagn* 21(8): 642-648.
7. Couzin, D. A., N. Haites, et al. (1986). "Partial trisomy 7 (q32----qter) syndrome in two children." *J Med Genet* 23(5): 461-465.
8. Chen, C. P., Y. N. Su, et al. (2012). "Rapid aneuploidy diagnosis by multiplex ligation-dependent probe amplification using uncultured amniocytes in pregnancy with major fetal structural abnormalities." *Taiwan J Obstet Gynecol* 51(1): 123-128.
9. Felding, I. and F. Mitelman (1979). "A child with partial trisomy 7 and 20 inherited from the mother." *Hereditas* 91(1): 91-95.
10. Forabosco, A., A. Baroncini, et al. (1988). "The phenotype of partial dup(7q) reconsidered: a report of five new cases." *Clin Genet* 34(1): 48-59.
11. Gardner RM, S. G., Shaffer LG (2004). "Chromosome abnormalities and genetic counseling." New York: Oxford University Press: 314-318.
12. Goodman, B. K., K. Stone, et al. (1999). "Molecular cytogenetic analysis and clinical findings in a newborn with prenatally diagnosed rec(7)dup(7q)inv(7)(p22q31.3)pat." *Prenat Diagn* 19(12): 1150-1156.
13. Grace, E., G. R. Sutherland, et al. (1973). "Partial trisomy of 7q resulting from a familial translocation." *Ann Genet* 16(1): 51-54.
14. Haslam, J. S. and A. M. Norman (1992). "De novo inverted duplication of chromosome 7q." *J Med Genet* 29(11): 837-838.
15. Hoo, J. J., R. Lorenz, et al. (1982). "Tiny interstitial duplication of proximal 7q in association with a maternal paracentric inversion." *Hum Genet* 62(2): 113-116.
16. Johnson, D. D., V. V. Michels, et al. (1986). "Duplication of 7q31.2---7qter and deficiency of 18qter: report of two patients and literature review." *Am J Med Genet* 25(3): 477-488.
17. Kardon, N. B., L. Pollack, et al. (1983). "De novo duplication of the 7q11 leads to q22 region." *J Med Genet* 20(6): 471-473.
18. Lukusa, T. and J. P. Fryns (1998). "Syndrome of facial, oral, and digital anomalies due to 7q21.2-->q22.1 duplication." *Am J Med Genet* 80(5): 454-458.
19. Megarbane, A., P. Gosset, et al. (2000). "Chromosome 7q22-q31 duplication: report of a new case and review." *Am J Med Genet* 95(2): 164-168.
20. Ndah, B. V., J. A. Stead, et al. (2000). "Prenatal detection of trisomy for the entire long arm of chromosome 7." *J Med Genet* 37(7): 551-553.
21. Novales, M. A., C. Fernandez-Novoa, et al. (1982). "Partial trisomy for the long arm of chromosome 7. Case report and review." *Hum Genet* 62(4): 378-381.
22. Robinet, C., S. Douvier, et al. (2000). "Prenatal diagnosis of a partial trisomy 7q in two fetuses with bilateral ventriculomegaly." *Prenat Diagn* 20(11): 936-938.
23. Rodriguez, L., F. Lopez, et al. (2002). "Pure partial trisomy 7q: two new patients and review." *Am J Med Genet* 113(2): 218-224.
24. Rodriguez L., M.-F. L., Mansilla E., Blanco Soto P., Sanz FM. (2005). "Trisomía parcial 7q y monosomía subtelomérica 20p. Presentación clínica de un caso y revisión." *Revista de Dismorfología y Epidemiología* 4: 14-18.
25. Romain, D. R., H. Cairney, et al. (1990). "Three cases of partial trisomy 7q owing to rare structural rearrangements of chromosome 7." *J Med Genet* 27(2): 109-113.
26. Scelsa, B., F. M. Bedeschi, et al. (2008). "Partial trisomy of 7q: case report and literature review." *J Child Neurol* 23(5): 572-579.
27. Schimd M., W. J., Nestler H., Krone W. (1979). "Partial trisomy for the long arm of chromosome 7 due to familial balanced translocation between 5p and 7q." *Human Genetics* 49(3): 283-289.
28. Shojaei, A., F. Behjati, et al. (2013). "Partial trisomy 7q and monosomy 13q in a child with disorder of sex development: phenotypic and genotypic findings." *Gene* 517(1): 137-145.
29. Slavotinek, A., E. Maher, et al. (1997). "The phenotypic effects of chromosome rearrangement involving bands 7q21.3 and 22q13.3." *J Med Genet* 34(10): 857-861.
30. Speleman, F., B. Callens, et al. (2000). "Subtelomeric familial translocation t(2;7)(q37;q35) leading to partial trisomy 7q35-->qter: molecular cytogenetic analysis and clinical phenotype in two generations." *Am*

- J Med Genet 93(5): 349-354.
31. Stetten, G., L. L. Charity, et al. (1997). "A paternally derived inverted duplication of 7q with evidence of a telomeric deletion." *Am J Med Genet* 68(1): 76-81.
  32. Stratton, R. F., B. R. DuPont, et al. (1993). "Interstitial duplication of 7(q22-->q34)." *Am J Med Genet* 47(3): 380-382.
  33. Tchirikov, M., A. Merinsky, et al. (2010). "Prenatal diagnosis of a recombinant chromosome 7 resulting in trisomy 7q11.22 --> qter." *Am J Med Genet A* 152A(3): 721-725.
  34. Tsui, L. C. (1988). "Genetic markers on chromosome 7." *J Med Genet* 25(5): 294-306.
  35. Turleau, C., A. Rossier, et al. (1976). "[Partial 7 q trisomy. One or 2 syndromes? Apropos of a new case]." *Ann Genet* 19(1): 37-42.
  36. Verma, R. S., R. A. Conte, et al. (1992). "Tandem duplication of the terminal band of the long arm of chromosome 7 (dir dup (7)(q36----qter))." *J Med Genet* 29(5): 344-345.
  37. Vogel W. (1977). "Partial duplication 7q. In Yunis JJ (ed)." *New Chromosomal syndromes*: 185-195.
  38. Wahrman, J., M. M. Cohen, et al. (1978). "A long unidentifiable extra chromosomal segment--a possible duplication of human 7q." *Cytogenet Cell Genet* 20(1-6): 160-168.
  39. Winsor, E. J., C. G. Palmer, et al. (1978). "Meiotic analysis of a pericentric inversion, inv(7) (p22q32), in the father of a child with a duplication-deletion of chromosome 7." *Cytogenet Cell Genet* 20(1-6): 169-184.
  40. Xiao, B., X. Ji, et al. (2011). "[A case with partial trisomy 7 (q34-->qter) derived from a paternal reciprocal translocation t(7;14)(q34;q32)]." *Zhonghua Yi Xue Yi Chuan Xue Za Zhi* 28(6): 654-657.
  41. Zelante, L., A. I. Croce, et al. (2003). "Interstitial "de novo" tandem duplication of 7(q31.1-q35): first reported case." *Ann Genet* 46(1): 49-52.